

CASE REPORT

Intrathoracic Displacement of Fractured Right Humeral Head: A Case Report

Ali Sadighi, MD¹; Touraj Asvadi Kermani, MD²; Parham Maroufi, MD³; Kosar Tarvirdizade, MD⁴; Atabak A.Kermani, MD⁵

Research performed at Tabriz University of Medical Sciences, Tabriz, Iran

Received: 24 December 2018

Accepted: 06 March 2019

Abstract

Intrathoracic displacement of the humeral head is a very uncommon condition and can be life threatening due to lung or heart injuries. There is a report of this condition where intrathoracic bone fragment was missed. Because of rare incidence there is no guideline for approach and treatment of this condition.

We hereby present a case of intrathoracic displacement of fractured humeral head in a man due to a car roll-over accident.

This condition requires a concise team workup of trauma and orthopedic surgeons along with the physical therapists for the best possible decision making.

Displaced fractured humeral head into the thorax is a rare condition that needs more punctuality for on time diagnosis and team approach.

Level of evidence: V

Keywords: Fracture, Humeral head, Intrathoracic displacement

Introduction

Intrathoracic displacement of humeral head is a very uncommon condition and can be life threatening. Because of the rare incidence there is no guideline for approach and treatment of this condition (1). We hereby present a case of intrathoracic displacement of fractured humeral head in a man due to a car roll-over accident and discuss how not to miss and how to approach these patients?

The previous reports on management of such cases have been: non-operative, fragment removing from thorax with thoracoscopy or thoracotomy and open reduction with internal fixation, hemi-arthroplasty, total arthroplasty, or arthrodesis (2, 3). Rib fixation had also been recommended in one study (2). The current case is reported in line with the SCARE criteria (4).

Case presentation

A 47 years old right-handed male, was presented to Meshkin Shahr hospital as a motor vehicle accident multi-trauma victim in a rollover type car accident. He was the car driver and airbags were deployed at the time of accident and the car speed was unknown. The initial encounter was done by EMS team and the patient was transferred to hospital with cervical collar while immobilized in supine position on the backboard. His GCS (Glasgow Coma Scale) was 15. He was tachypneic, tachycardiac, and dyspneic with diminished respiratory sounds on the right side. A chest-tube was inserted at his right-side and 250cc bloody secretion was drained. The patient was stabilized and his vital signs were significantly improved. He had no history of disease or drug use until the time of injury. In physical examination

Corresponding Author: Touraj Asvadi Kermani, Department of surgery, Imam Reza Hospital, Tabriz University of Medical Science, Tabriz, Iran

Email: tooraj_asvadi2005@yahoo.com



THE ONLINE VERSION OF THIS ARTICLE
[ABJS.MUMS.AC.IR](http://abjs.mums.ac.ir)

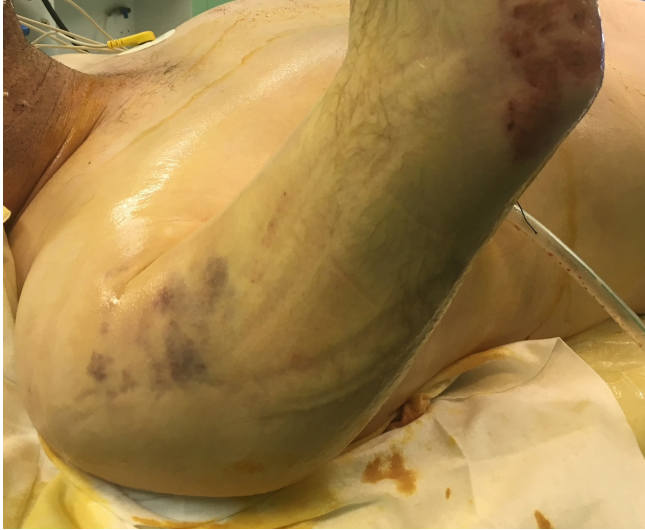

Figure 1. Right shoulder with deformity, swelling and ecchymosis without any open fracture or wound.

the right shoulder was deformed, swelled and ecchymotic, without any open fracture or wound [Figure 1]. The brachial, radial, and ulnar pulses were 2+ and bilaterally symmetric. Neurological examination of the right upper limb was not reliable due to the severe pain. Chest radiography showed right forearm dislocation and fracture of humeral head, glenoid, acromion, and posterior arch of the 3rd, 4th, and 5th ribs. The right

chest-tube as well as the humeral head was seen in the right hemi-thorax [Figure 2]. FAST was negative and radiologic evaluation for head and neurologic trauma was not significant. Examinations of other extremities were normal. The spiral computed tomography of chest and 3-Dimensional reconstruction corroborated the finding of radiography [Figure 3].

The patient was transferred to the operating room and antero-lateral thoracotomy from the 5th intercostal space was done by a trauma surgeon. Blood and hematoma were evacuated from the thoracic cavity. In exploration, the 3rd, 4th, and 5th ribs fractures were visualized with minimal displacement and did not need surgical fixation. Bupivacaine 0.5% was injected into the periosteum of the ribs around the site of fracture for pain relief. The lung was intact with no active bleeding. A single bone piece which was the humeral head was removed from the thoracic cavity [Figure 4]. The thorax was closed after inserting two chest-tubes.

Figure 4. The Head of humerus

After thoracic surgery, orthopedic operation was done on the same day and with deltopectoral incision approaching the right shoulder. In exploration of the shoulder, rotator cuff muscles with tuberosities entirely were torn. Due to the fracture pattern and strong probability of axillary nerve damage, orthopedic surgeons decided to perform an open reduction internal fixation (ORIF) of the humeral head. The humeral head was fixed with PHILOS plate to the humeral shaft. Glenoid also, was reduced and fixed with two bolts. Then the tuberosities were fixed on plate with fiber wires and controlled with C-Arm X-Rays [Figure 5].

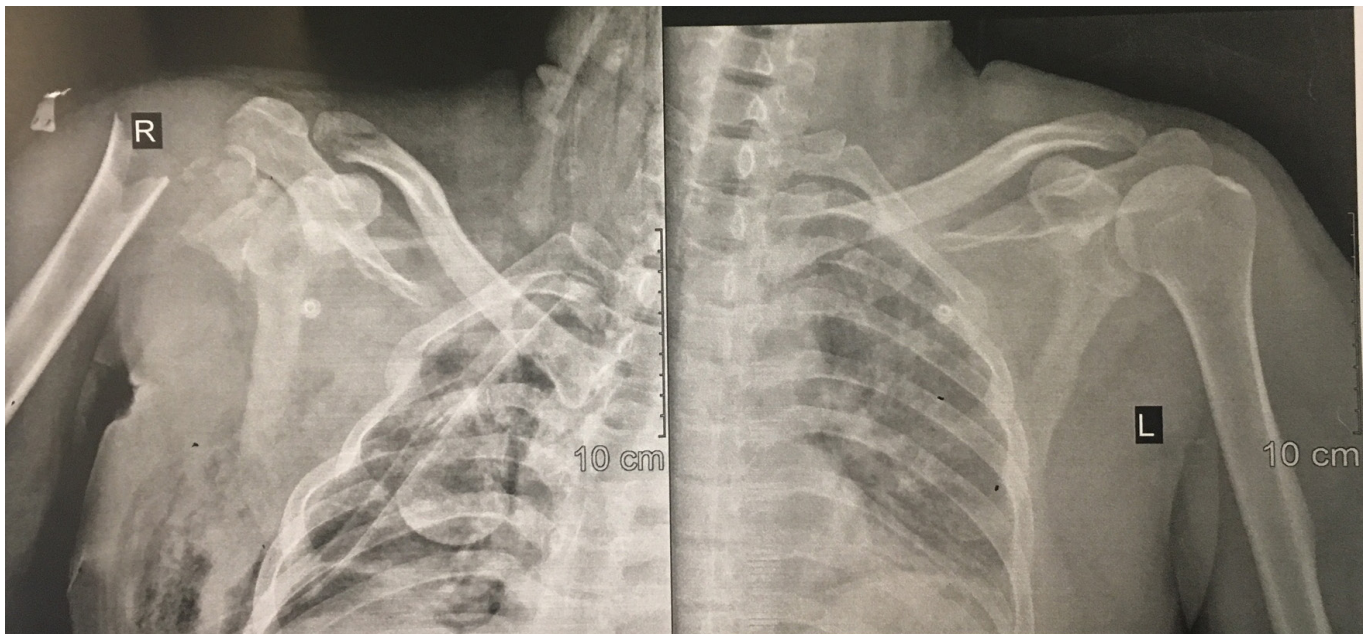


Figure 2. Chest radiography shows forearm dislocation and fracture of Humeral head, glenoid, acromion and posterior arch of 3rd, 4th and 5th ribs. Right chest-tube and head of humerus are seen in right hemi-thorax.

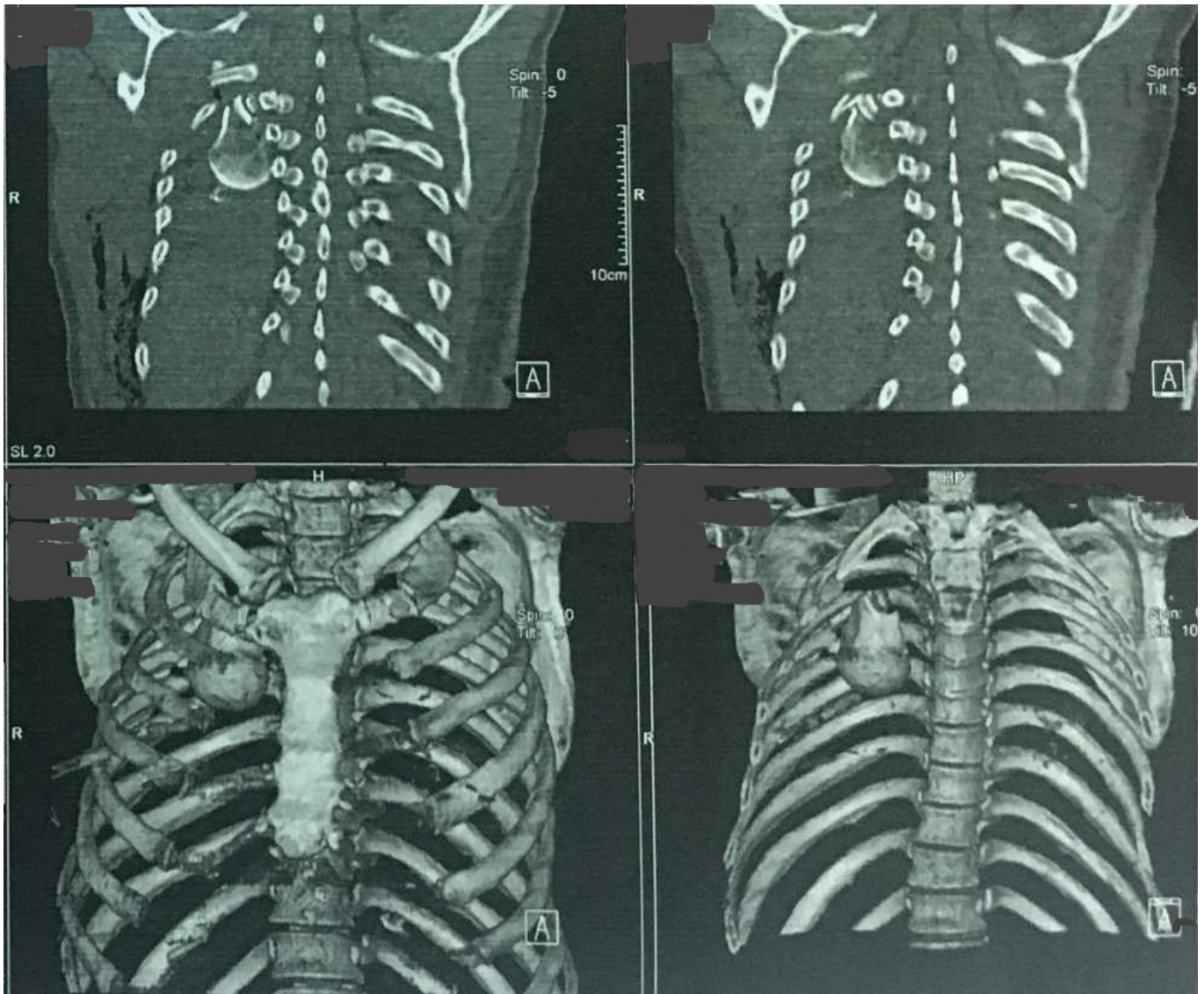


Figure 3. The spiral computed tomography of chest with 3-Dimensional reconstruction. Head of humerus in right hemithorax.

Figure 5. Humerus after open reduction and internal fixation of humeral head to the shaft of humerus.

As the vessels of the bone fragment were damaged, we expected the necessity for hemiarthroplasty in the future because of the probability of avascular necrosis (AVN). Also, we expected that axillary nerve (a part of brachial plexus) could have been damaged. His arm was positioned using an arm sling and the pain was controlled with continuous intravenous narcotic analgesis. The pain decreased after 4 days and passive range of motion exercises were started by physical therapy team. The chest-tubes were removed and the patient was discharged after ten days with outpatient physical therapy. Follow-up appointments were scheduled at the time of discharge.

Discussion

So far a total of 24 cases of intrathoracic displacement of fractured humeral head have been reported in English and non-English articles (6). This condition requires high-energy trauma (1). There are two hypotheses about the mechanism of this condition: severe and sudden trauma to the shoulder in position of abduction and external rotation or post-traumatic migration of humeral head to thorax because of the force along the humeral shaft (2, 3, 6). Fragility between the upper ribs facilitates this migration (5).

The bone fragments in thorax may not be seen only in radiographic evaluation due to the hematoma or lung contusion. Absence of wound may worsen this misdiagnosis. Hence, computed tomography (CT scan)

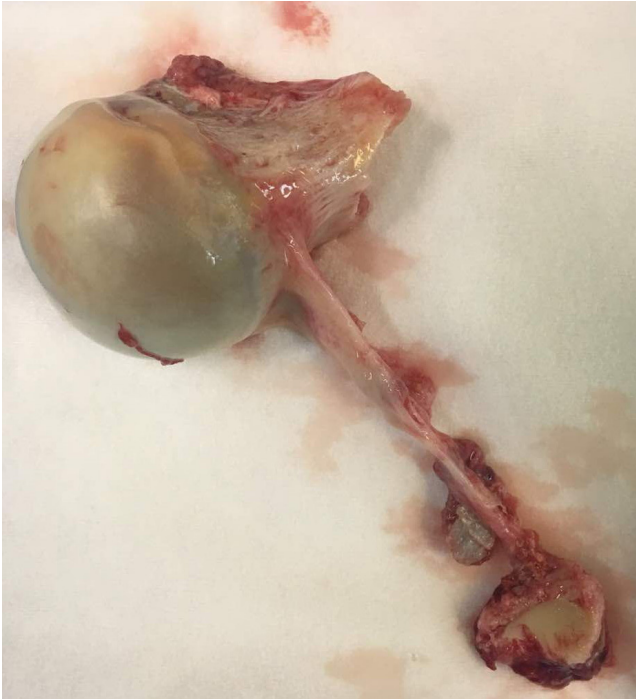

Figure 4. The Head of humerus.

must used when the proximal part of the humerus cannot be seen.

Some of similar cases have been reported to be treated non-surgically with traction and close reduction. The bone fragments had been left in the lung with no complications. However, those bone particles can migrate and cause dangerous injuries to vessels and organs. They can also act as a nidus for infection although they are sterile (2, 6).

In another report Video- Assisted Thoracic Surgery (VATS) was used with minithoracotomy (1, 3). Hawkes et al. recommended the posterolateral thoracotomy that provide good exposure for removing the bone fragments and also fixing the fractured ribs at the same time, but it may be a complicated surgery with higher morbidity and mortality (1, 2).

ORIF is the recommended surgery for shoulder and AVN can be the most significant complication of this approach (6). Hemi-arthroplasty has been reported as the most common surgery for shoulder in these cases (5).

Team-work was the key in managing this patient and providing the best care. Traumatologist, orthopaedic surgeon, physical therapist and well-trained nurses and technicians were all part of the great medical and surgical team.

Patient consent: Written informed consent was obtained from the patient for publication of this case

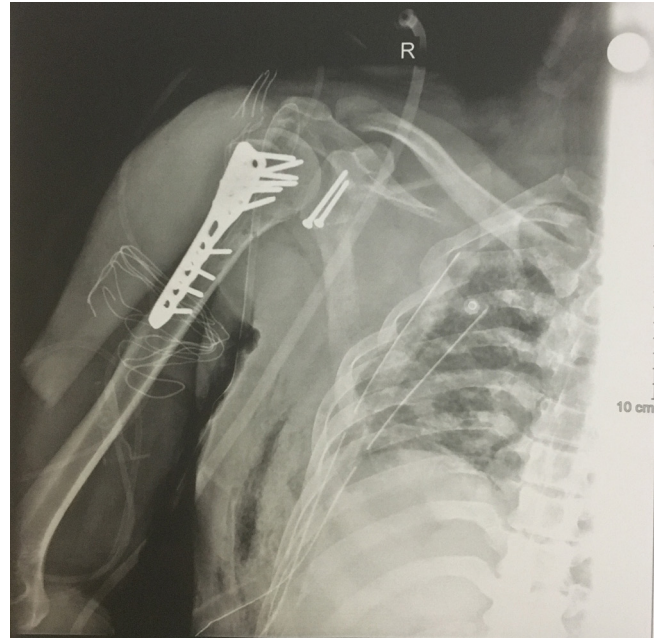


Figure 5. Humerus after open reduction an internal fixation of head of humerus to shaft of humerus.

report and accompanying images. A copy of the written consent is available for review by the Editor-in-Chief of this journal on request.

Acknowledgements

The authors would like to thank for the corporation of all staff in operation rooms of Imam Reza and Shohada Hospitals and physical therapist as well as the patient himself.

Ali Sadighi MD¹

Touraj Asvadi Kermani MD²

Parham Maroufi MD³

Kosar Tarvirdizade MD⁴

Atabak A.Kermani MD⁵

1 Shohada Hospital, Tabriz University of Medical Science, Tabriz, Iran

2 Tabriz University of Medical Science, Tabriz, Iran

3 Shohada Hospital, Tabriz University of Medical Science, Tabriz, Iran

4 Ostad Shahriyar Hospital, Tabriz University of Medical Science, Tabriz, Iran

5 Cedar Rapids Medical Education Foundation, Iowa, USA

References

1. Rupprecht H, Ghidau M, Gaab K. Severe Thoracic Trauma Due to an Intrathoracic Dislocation of a Fractured Humeral Head in an Aged Patient; A Case Report. *Bull Emerg Trauma*. 2017;5(3):212-214.
2. Hawkes T, Parra M, Shrock K. Intrathoracic Fracture-Dislocation of the Proximal Humerus Treated with Rib Fixation and Shoulder Arthroplasty. *Am J Orthop*. 2014;43(4):E74-E78.
3. Tsai YM, Lee Sh.Ch, Shen P.H, Chang H, Cheng Y.L. Intrathoracic Displacement of a Fractured Humeral Head due to Blunt Trauma. *Ann Thorac Cardiovasc Surg*. Advance Published Date: April 5, 2013.
4. Agha RA, Fowler AJ, Saetta A, Barai I, Rajmohan S, Orgill DP, for the SCARE Group. The SCARE Statement: Consensus-based surgical case report guidelines. *International Journal of Surgery* 2016;34:180-186.
5. Juniora W.C.S, Santosb P.S.D. Intrathoracic fracture-dislocation of the humerus- case report and literature review. *Rev Bras Ortop*. 2017;52(2):215-219.
6. Kocer B, Gulbahar G, Aktekin C.N, Gunal N, Birinci B, Dural K, Sakinci U. Intrathoracic Humeral Head Fracture-Dislocation: Is Removal of the Humeral Head Necessary? *Ann Thorac Surg*. 2007;84:1371-2.